

University for Business and Technology in Kosovo

UBT Knowledge Center

UBT International Conference

2017 UBT International Conference

Oct 28th, 11:00 AM - 12:30 PM

Herniated lumbar disc & Nursing care

Besnik Elshani

University Clinical Center of Kosova, besnik.elshani@ubt-uni.net

Salih Krasniqi

University Clinical Center of Kosova

Rexhep Gjyliqi

University Clinical Center of Kosova

Follow this and additional works at: <https://knowledgecenter.ubt-uni.net/conference>



Part of the [Medicine and Health Sciences Commons](#)

Recommended Citation

Elshani, Besnik; Krasniqi, Salih; and Gjyliqi, Rexhep, "Herniated lumbar disc & Nursing care" (2017). *UBT International Conference*. 285.

<https://knowledgecenter.ubt-uni.net/conference/2017/all-events/285>

This Event is brought to you for free and open access by the Publication and Journals at UBT Knowledge Center. It has been accepted for inclusion in UBT International Conference by an authorized administrator of UBT Knowledge Center. For more information, please contact knowledge.center@ubt-uni.net.

Herniated Lumbar Disc and Nursing Care

Besnik Elshani^{1,4}, Salih Krasniqi^{2,4}, Rexhep Gjyliqi^{3,4}

¹Neurosurgery Clinic, University Clinical Center of Kosovo, Pristina 10000, Republic of Kosovo

²Abdominal Clinic, University Clinical Center of Kosovo, Pristina 10000, Republic of Kosovo

³Anesthesiology Clinic, University Clinical Center of Kosovo, Pristina 10000, Republic of Kosovo

⁴Faculty of Nursing, UBT – Higher Education Institution, Lagjja Kalabria, 10000 p.n., Prishtine, Kosovo
besnik.elshani@ubt-uni.net

Abstract: Spinal disc herniation, also known as a slipped disc, is a medical condition affecting the spine in which a tear in the outer, fibrous ring of an intervertebral disc allows the soft, central portion to bulge out beyond the damaged outer rings. Disc herniation is usually due to age-related degeneration of the outer ring, known as the anulus fibrosus, although trauma, lifting injuries, or straining have been implicated as well. Tears are almost always postero-lateral (on the back of the sides) owing to the presence of the posterior longitudinal ligament in the spinal canal.[1] This tear in the disc ring may result in the release of chemicals causing inflammation, which may directly cause severe pain even in the absence of nerve root compression. Disc herniations are normally a further development of a previously existing disc protrusion, a condition in which the outermost layers of the anulus fibrosus are still intact, but can bulge when the disc is under pressure. In contrast to a herniation, none of the central portion escapes beyond the outer layers. Most minor herniations heal within several weeks. Anti-inflammatory treatments for pain associated with disc herniation, protrusion, bulge, or disc tear are generally effective. Severe herniations may not heal of their own accord and may require surgery. The condition is widely referred to as a slipped disc, but this term is not medically accurate as the spinal discs are firmly attached between the vertebrae and cannot "slip" out of place. Lumbar disc herniations occur in the lower back, most often between the fourth and fifth lumbar vertebral bodies or between the fifth and the sacrum. Symptoms can affect the lower back, buttocks, thigh, anal/genital region (via the perineal nerve), and may radiate into the foot and/or toe. A hernia in the lumbar region often compresses the nerve root exiting at the level below the disk. Thus, a herniation of the L4/5 disc will compress the L5 nerve root. In the Neurosurgery Clinic in Pristina we have analyzed the operating cases of Herniated lumbar disc during the period 2014/2016 ie a period of three years. In total, there were 673 cases operable in this period, of which 418 were females and 256 male males. In 2014, 174 patients were operated, out of which 98 were female and 74 male males. In 2015, 220 patients were operated, 145 of them were female and 65 of male males. In 2016, 289 patients were operated, including 175 females and 15 males. We have also analyzed the nursing treatment, where according to our statistics, the patients during these three years have stayed and are treated in a ward with an average of 6.1 days.

Keywords: Spinal disc herniation, nursing, herniated lumbar disc.

Introduction

Herniated lumbar disc is spinal discs which plays a crucial role in the lower back, serving as shock absorbers between the vertebrae, supporting the upper body, and allowing a wide range of

movement in all directions. If a disc herniates and leaks some of its inner material, though, the disc can quickly go from easing daily life to aggravating a nerve, triggering back pain and possibly pain and nerve symptoms down the leg.



Figure 1. Patient with a chronic back pain [1,2].

Between each two spinal bone there is a weight absorbing substance that makes weight distribution equally in the body. This subject is called a disk and just pushing this part and getting out of the place by creating the pressures on the spinal cord causes the so-called herniated disc. The disc has a thickness of 4-6 mm and also hampers the vertebrae of the backbone. First, a cut may occur when the disc is blown without breaking the fibrous annulus. Secondly, a disc can be prolapsed where nucleus pulposus migrates into the outer fibers of the annulus fibrosus. Thirdly, there may be disc extrusion. In this case the annular fibrous is perforated and the core material moves into the epidural space. Finally, a seized disc may occur, as fragments from the annulus fibrosus and nucleus pulposus are out of the proper disc.

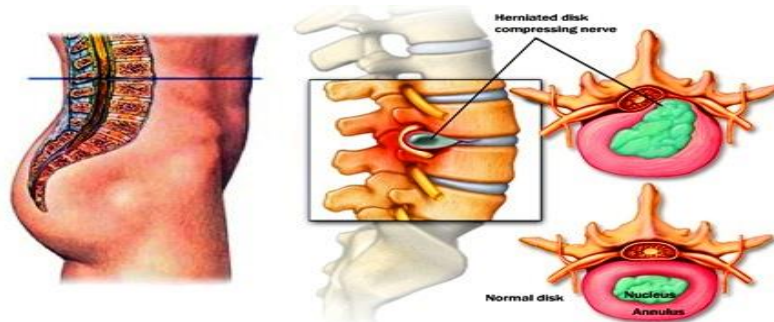


Figure 2. Herniated Lumbar Disc [3].

Disc herniation symptoms usually starts for no apparent reason. Or they may occur when the person lifts something heavy or twist the low back, motions that put added stress on the disc. Lumbar herniate are the widespread medical problem discs are class discs are a common medical most often affecting people age 35 to 50. Men have roughly twice the risk for lumbar herniated discs compared with women.

Jobs that require heavy lifting and other physical labor have been linked to a greater risk of developing a lumbar herniated disc. Pulling, pushing, and twisting actions can add to risk if they're done repeatedly. Excess weight makes one more likely to experience a lumbar herniated disc and 12 times more likely to have the same disc herniate again, called a recurrent disc herniation, after a microdiscectomy surgery. Experts believe that carrying extra weight increases the stress on the lumbar spine, making people who are obese more prone to herniation.

The leg pain is typically worse than low back pain. If the pain radiates along the path of the large sciatic nerve in the back of the leg, it is referred to as sciatica or a radiculopathy. The most noticeable symptoms are usually described as nerve pain in the leg, with the pain being described as searing, sharp, electric, radiating, or piercing.

Herniation occurs when the nucleus (nucleus) in the center of the disk is pressed out of its normal space. The nucleus pushes the anulus (ligamentous ring) causing the disc to protrude from the outside. In some cases the herniated disc completely by the anulus and the disc is pressed.

First, a proper neurological examination is recommended by a specialist.

L5 nerve impingement (at the L4-L5 level) from a herniated disc can cause symptoms such as weakness in extending the big toe and potentially in the ankle, which leads to difficulty with the heel-to-toe motion in walking. This weakness is called foot drop. Numbness and pain may be felt on top of the foot, and the pain may also radiate into the buttock. S1 nerve impingement (at the L5-S1 level) from a herniated disc may cause loss of the ankle reflex and/or weakness that makes it difficult for patients to stand on their toes or on the ball of the foot. Numbness and/or pain can radiate along the outside of the calf, down to the sole or outside of the foot and the toes.

Symptoms attributed to a herniated lumbar disc may have other causes. A thorough physical exam, medical evaluation, and sometimes diagnostic imaging tests are commonly needed to determine the source of pain and other symptoms. MRI (magnetic resonance imaging) usually provides the most accurate assessment of the lumbar spine area, showing where a herniation has occurred and which nerves are affected. Often, an MRI scan is ordered to aid surgical planning. It can show where the herniated disc is and how it is impinging on the nerve root.

The doctor may recommend non-prescription non-steroidal anti-inflammatory medications (NSAIDs) such as ibuprofen or naproxen to treat pain and inflammation. Muscle spasms may accompany a lumbar herniated disc, and these prescription medications may offer relief from the painful spasms. Bed rest for severe pain is best limited to one or two days, as extended rest will lead to stiffness and more pain. After that point, light activity and frequent movement—with rest breaks as needed—is advised. Heavy lifting and strenuous exercise should be avoided.

Physical therapy is important in teaching targeted stretching and exercises for rehabilitation. The program may also teach the patient safer ways to perform ordinary activities, such as lifting and walking. Spinal manipulations performed by a chiropractor or osteopath may also ease pain and provide a better healing environment. Cognitive behavior therapy can be helpful in managing sciatica pain. The therapy helps people control and change self-defeating behaviors. A therapist helps the patient in face-to-face or online sessions. A therapist may also be helpful in teaching techniques such as mindful meditation and visualization to reduce pain. Massage therapy can ease back pain by increasing blood circulation, relaxing muscles, and releasing the body's natural pain relievers, called endorphins.

Neurological symptoms caused by the herniation may include difficulty lifting the foot when walking or standing on the ball of the foot, a condition known as foot drop.

A loss of bladder or bowel control, lower back pain, numbness in the saddle area, and/or weakness in both legs are signs of a rare but serious condition called cauda equina syndrome. This pressure and swelling of the nerves at the end of the spinal column can lead to paralysis and other permanent impairments if treatment is delayed. Emergency medical treatment, which may include testing and surgery, is needed if these symptoms occur.

If the pain and other symptoms of a lumbar herniated disc persist after six weeks, surgery is often considered. A lumbar herniated disc is the most common reason for spine surgery in adults during their working years.

Surgery may be recommended if:

- There is severe pain and the person is having difficulty maintaining a reasonable level of daily functions, such as standing or walking.
- The person is experiencing progressive neurological symptoms, such as worsening leg weakness, and/or numbness
- There is a loss of bowel and bladder functions.

- Medication, physical therapy, and/or other nonsurgical treatments have not significantly eased symptoms.

In some cases, surgery is needed before the patient has completed six weeks of nonsurgical care.

Two minimally invasive procedures, microdiscectomy and endoscopic microdiscectomy, are most commonly recommended for lumbar herniated discs. These procedures take the pressure off the nerve root and provide a better healing environment for the disc.

Objectives

The purpose of this paper is to familiarize yourself with the lumbar disc, review of cases that have been operated at UCKK Clinic of Neurosurgery in Prishtina for a period of three years as well as treatment and nursing rehabilitation of patients. Main objectives:

- Recognition of lumbar disc, clinical neurological symptoms, nursing treatment and rehabilitation
- Determination of indicators for the lumbar disc in the period 2014-2016
- Operations of clinical cases
- Nursing Rehabilitation
- Health education of patients for herniated lumbar disc

Material and Methods

- In the Neurosurgery Clinic in Prishtina we have analyzed the operating cases of Herniated lumbar disc during the period 2014/2016 in the three-year period.
- Altogether, there were 673 cases operated, out of which 418 were females and 256 male males.
- In 2014, 174 patients were operated, including 98 female and 74 males
- In 2015, 220 patients were operated, including 145 women and 65 men.
- In 2016, 289 patients were operated, including 175 female and 15 male males.
- We have also analyzed the nursing treatment where, according to our statistics, patients during these three years have stayed and are treated in the ward with an average of 6.1 days.

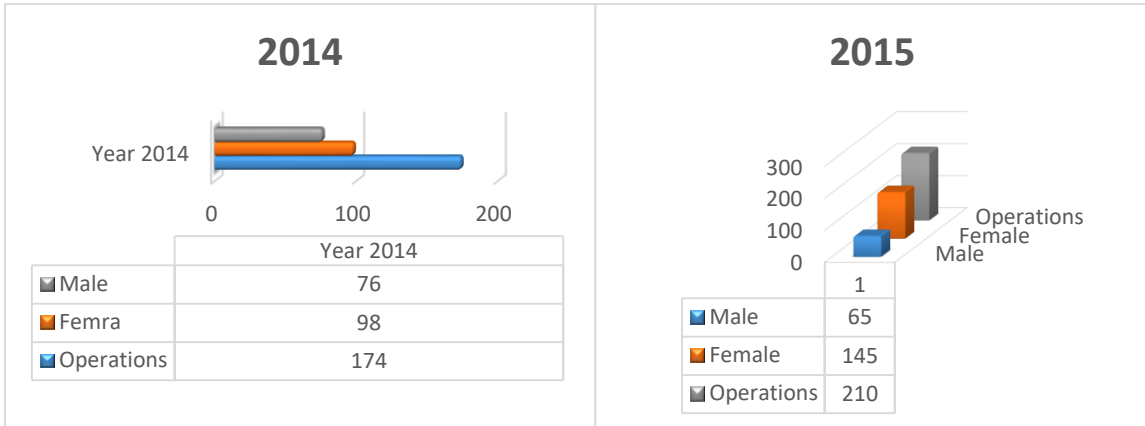


Figure 3. Statistics of Operations in 2014 **Figure 4.** Statistics of Operations in 2015

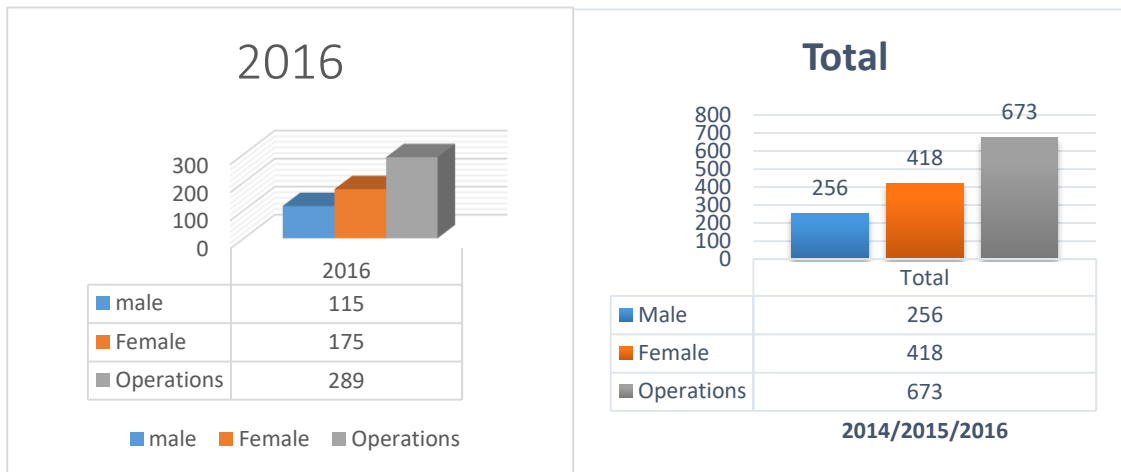


Figure 5. Statistics of Operations in 2016

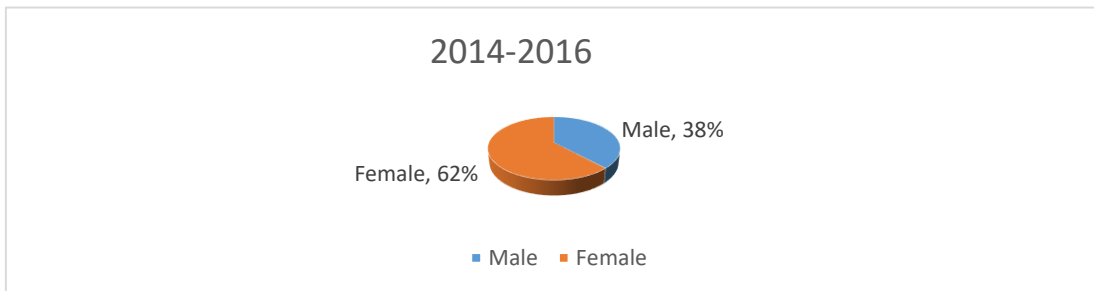


Figure 6. Statistics of Operations in 2014-2016

Place to be given IM injection

♣ Nurses always be careful not to inject hurt the sciatic nerve.

♣ injecting the needle should always be done on upper quadrant outside of the muscle gluteus medius

Keeping adequate breathing and vital signs

♣ Monitoring of breathing

♣ Vital Signs

♣ Pulmonary physiotherapy

♣ Psychosocial assessment

♣ Communication

Excess weight makes one more likely to experience a herniated lumbar disc and 12 times more likely to have the same herniated disc again, called a recurrence disc herniation after a microdiscectomy operation. Experts believe that maintaining extra weight increases stress in the lumbar spine, causing obese people to be more prone to herniated disc.

Nicotine limits blood flow to spinal discs, which speeds up disc degeneration and hampers healing. A degenerated disc is less pliable, making it more likely to tear or crack, which can lead to a herniation. The medical literature is mixed on whether people who smoke are at greater risk for a new herniation following a discectomy.

The medical literature has shown a hereditary tendency for disc degeneration, and disc degeneration is associated with an increased risk for a herniation. One extensive study found that a family history of lumbar herniated discs is the best predictor of a future herniation

Mobility support

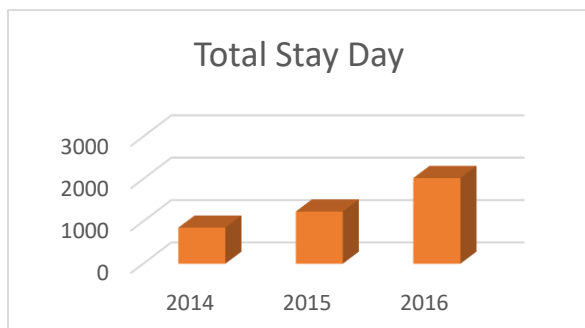
- Kinetic positioning in the bed
- Performance of bed exercises
- Protecting skin integrity

Support for urinary and intestinal elimination

- Urinal function monitoring
- Urine retention monitoring
- Administration of liquids and antibiotics
- Urinary catheterization
- Evaluation of intestinal noises
- Use of calories and proteins
- Use of laxatives
- Climate cleaner

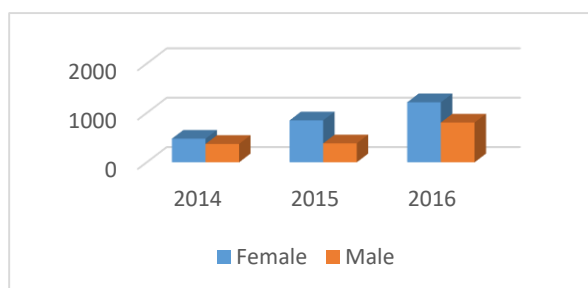
Patient Activation and Pain Reduction

- Stress Management with Relaxing Therapy
- Neurogenic pain management
- Activating physical therapy



Year	Total Stay Day	Average Stay Day
2014	851	5.1
2015	1232	6
v2016	2022	7.2

Figure 7. Nursing treatment of cases operated at the Neurosurgery Clinic during the stay in the years.



Year	Female	Male
2014	479	372
2015	849	383
2016	1216	806

Figure 8. Operated and Day-Based Attitudes for the years.

Discussion

Surgery for a lumbar herniated disc has a high rate of success. One extensive medical study reported good or excellent results for 84% of those having a microdiscectomy and nearly 80% for those having an endoscopic microdiscectomy. Microdiscectomy and endoscopic microdiscectomy are particularly helpful in relieving leg pain, commonly called sciatica. These procedures have not been as successful in easing back pain, and are typically not performed if back pain is the main issue. One large study found that people who had surgery for a lumbar herniated disc experienced more improvement in symptoms for up to two years than those having nonsurgical treatment. While microdiscectomy and endoscopic microdiscectomy are considered low-risk procedures, all surgery has risks. About 10% of patients having a microdiscectomy will experience another disc herniation at the same location. A recurrence is more likely within the first three months, but also can happen years later. Multiple recurrences are typically addressed with lumbar fusion surgery. This removes all the disc material and stops movement of the discs. In our study and practice the cases were operated with the method of microdiscectomy and standard discectomy.

Conclusion

At the Neurosurgery Clinic in Pristina we have analyzed the operating cases of Herniated lumbar disc during the period 2014/2016 ie the three-year period. Altogether, there were 673 cases operated out of which 418 were females and 256 male. In 2014, 174 patients were operated, of which 98 were female and 74 male. In 2015, 220 patients, of them 145 of the female and 65 of the male gender. In 2016 289 patients were operated, including 175 female and 114 male.

We have also analyzed the nursing treatment where, according to our statistics, the patients during these three years have stayed and have been treated in the ward with an average of 6.1 days. In our study in the cases of operation and day stay in hospital have dominated females with the patient and doctor, plan a pain control regimen. Encourage the patient to express his concerns about the disorder. Urge the patient to perform as much self-care as his immobility and pain allow. Help the patient identify and perform care and activities that promote rest and relaxation. Use antiembolism stockings, as prescribed, and encourage the patient to move his legs, as allowed. Assess the patient's pain status and his response to the pain-control regimen. Perform neurovascular checks of the patient's legs such as color, motion, temperature, and sensation. Monitor vital signs, and check for bowel sounds and abdominal distention. Teach the patient about treatments, which include bed rest and pelvic traction. Urge the patient to maintain an ideal body weight to prevent lordosis caused by obesity. Discuss all prescribed medications with the patient. If surgery is required, explain all preoperative and postoperative procedures and treatments to the patient and his family.

References

1. Fardon DF, Milette PC. Nomenclature and classification of lumbar disc pathology: recommendations of the Combined Task Forces of the North American Spine Society, American Society of Spine Radiology, and American Society of Neuroradiology. *Spine* 2001;26:E93–E113
2. Borenstein DG, O'Mara JW Jr, Boden SD, et al. The value of magnetic resonance imaging of the lumbar spine to predict low-back pain in asymptomatic subjects. *J Bone Joint Surg Am* 2001;83-A:1306–1311.
3. Kelsey JL, Githens P, O'Connor T, et al. Acute prolapsed lumbar intervertebral disc: an epidemiologic study with special reference to driving automobiles and cigarette smoking. *Spine* 1984;9:608–613.
4. Vroomen PC, de Krom MC, Slofstra PD, et al. Conservative treatment of sciatica: a systematic review. *J Spinal Disord* 2000;13:463–469.
5. Gibson JNA, Waddell G. Surgical interventions for lumbar disc prolapse. In: *The Cochrane Library*, Issue 2, 2008. Chichester, UK: John Wiley & Sons Ltd. Search date 2007.
6. Liu J, Zhang S. Treatment of protrusion of lumbar intervertebral disc by pulling and turning manipulations. *J Tradit Chin Med* 2000;20:195–197.

Figures:

1. https://www.google.com/search?q=back+pain&source=lnms&tbm=isch&sa=X&ved=0ahUKEwjl6z-zdDXAhXHOxoKHX8ABDwQ_AUICyG&biw=1366&bih=637#imgdii=onnNFYCMxh4o_M:&imgcr=zqs5GEv7pSIYaM:
2. https://www.google.com/search?q=back+pain&source=lnms&tbm=isch&sa=X&ved=0ahUKEwjl6z-zdDXAhXHOxoKHX8ABDwQ_AUICyG&biw=1366&bih=637#imgcr=hJDFqgF3eds4IM:
3. https://www.google.com/search?q=herniated+lumbar+disc&source=lnms&tbm=isch&sa=X&ved=0ahUKEwi_-6bhy9DXAhWGYIAKHxpSB34Q_AUICyG&biw=1366&bih=637#imgcr=ok_IFr8OS7Kf5M: